
CHAPTER

13

Support and Movement

Animation13.1: Torso
Source & Credit: Usahobby

The organisms with greater sizes need support to keep their body mass as one unit. This is particularly true for the organisms that live on land. We know that movement and locomotion are characteristics of animals. "Movement" is a general term meaning the act of changing place or position by entire body or by its parts. There are two types of movements i.e. movements of body parts and locomotion. Locomotion is the movement of an animal as a whole from one place to another.

In this chapter, we will study human skeletal system (skeleton) which is primarily responsible for support and movement.

The skeletal system of some invertebrates e.g. arthropods, is on the outside of the body, and is called exoskeleton.

13.1 Human Skeleton

Skeletal system or **skeleton** is defined as the framework of hard, articulated structures that provide physical support, attachment for skeletal muscles, and protection for the bodies of animals. Like other vertebrates, the human skeleton is on the inside of body and is called **endoskeleton**. In the living body, the skeleton is very much alive. Bones and cartilages are made of living cells and also have nerves and blood vessels in them. They grow and have the ability to repair themselves.

13.1.1 Role of Skeletal System

The big functions of skeletal system are protection, support and movements. In our body, skeleton works very closely with the muscular system to help us move. Similarly, skeleton provides protection to many internal organs e.g. skull protects brain, vertebral column protects spinal cord and ribs protect most of our other internal organs. Vertebral column also provides the main support to our body mass.

13.1.2 Bone and Cartilage

Overall, the human skeleton is made of bony framework but in certain parts, this framework is supplemented by cartilage.

a. Cartilage

Cartilage is a dense, clear blue-white firm connective tissue (but less strong than bone). The cells of cartilage are called **chondrocytes**. Each chondrocyte lies in a fluid space called **lacuna** present in the **matrix** of cartilage (Fig. 13.1). The matrix of cartilage contain also **collagen** fibres. Blood vessels do not enter cartilage. There are three types of cartilage.

Recalling

Cartilage and bone are types of connective tissue in animals. Most connective tissues contain collagen fibres in a matrix.

Recalling

Tendons and ligaments are other connective tissues that contain tightly packed collagen fibres.

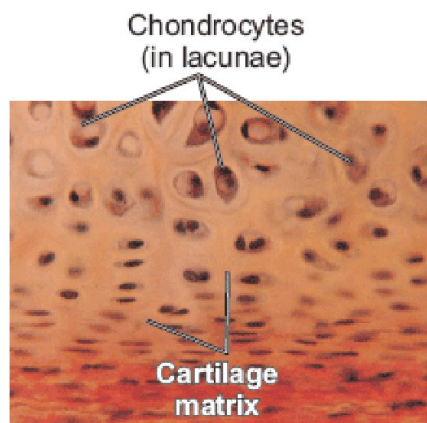


Figure 13.1: Chondrocytes in cartilage matrix

Hyaline cartilage is strong yet flexible. It is found covering the ends of the long bones, in the nose, larynx, trachea and bronchial tubes.

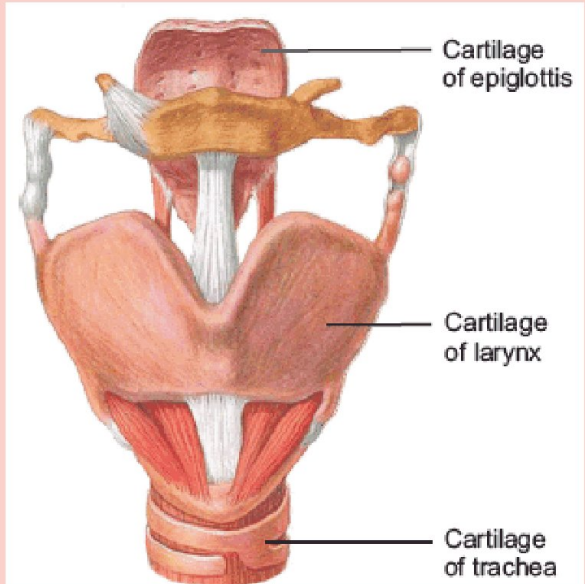
Elastic cartilage is similar in structure to hyaline cartilage. It is also quite strong but has elasticity due to a network of elastic fibres in addition to collagen fibres. It is found in epiglottis, pinna etc.

Fibrous cartilage is very tough and less flexible due to large number of thick collagen fibres present in knitted form. It is found in intervertebral discs.

b. Bone

Bone is the hardest connective tissue in body. Bones not only move, support and protect the various parts of body but also produce red and white blood cells and store minerals.

What types of cartilage these are?



Babies are born with about 300 soft bones. Some of these bones later fuse together, so that the adult skeleton has 206 hard bones.

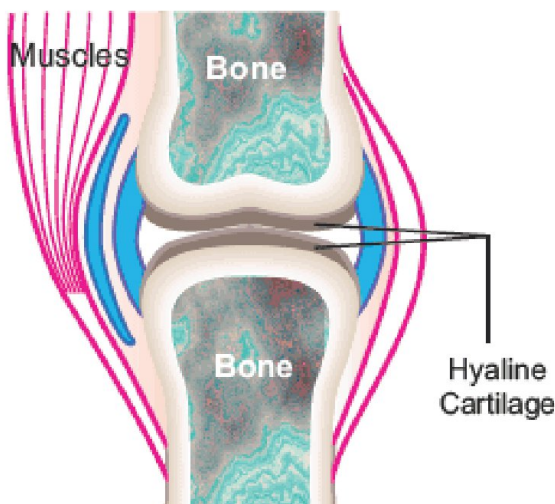


Figure 13.2: Hyaline cartilage

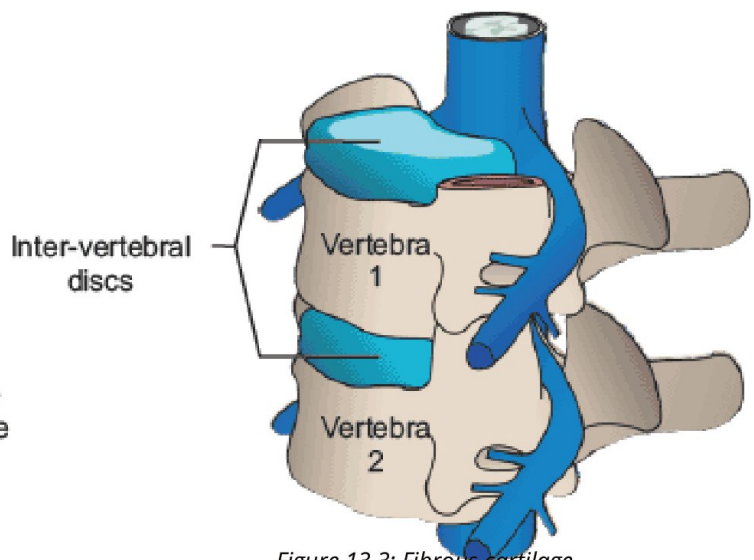


Figure 13.3: Fibrous cartilage

The hard outer layer of a bone is called compact bone while the interior of bone is soft and porous. It is called spongy bone. Spongy bone contains blood vessels and bone marrow (Fig. 13.4).

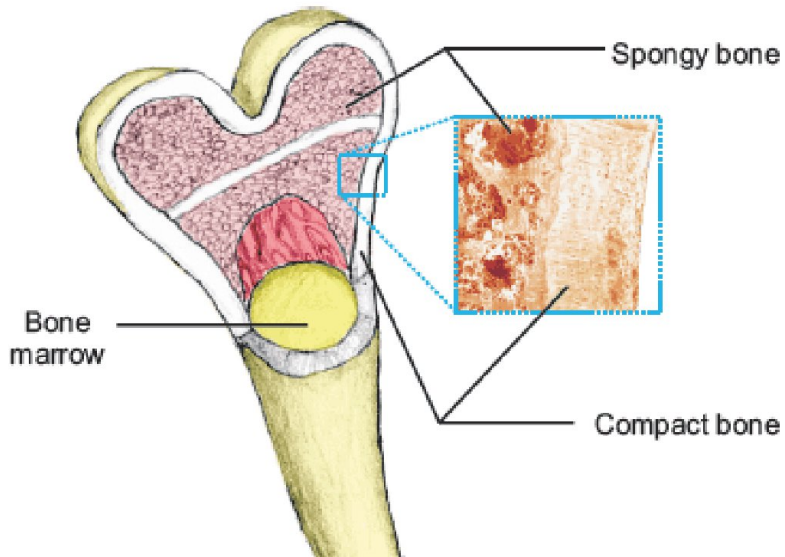


Figure 13.4: Compact and spongy bone

Animation13.3: Marvelous structure,
Source & Credit: Wmt

Like cartilage, the matrix of bones also contains collagen. But it also contains minerals e.g. calcium and phosphate. We know that cartilage contains a single type of cell. On the other hand, bones contain different types of cell. The mature bone cells are called **osteocytes**.

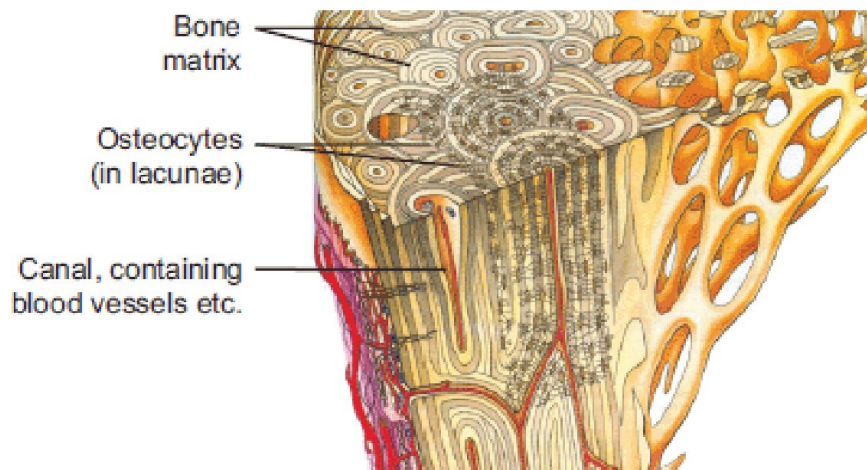

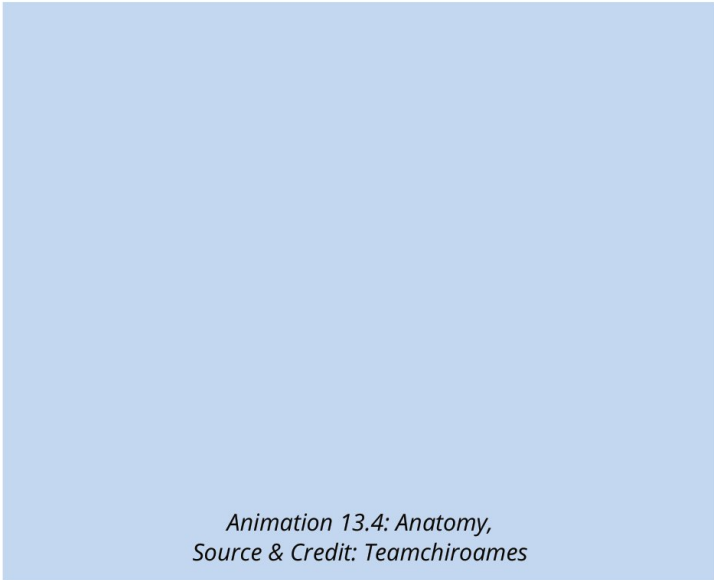


Figure 13.5: The internal structure of bone

13.1.3 Components of Human Skeleton

The 206 bones in the adult human skeleton are organized into a longitudinal axis i.e. axial skeleton, to which appendicular skeleton is attached.

a. Axial skeleton


Axial skeleton consists of the 80 bones in the head and trunk of body. It is composed of five parts. **Skull** contains 22 bones out of which 8 are cranial bones (enclosing the brain) and 14 are facial bones. There are 6 **middle ear ossicles** (3 in each ear). There is also a hyoid bone in neck. Vertebral column contains 26 bones (vertebrae). The **chest** is made of a chest bone called sternum and 24 (12 pairs) ribs.

b. Appendicular Skeleton

Appendicular skeleton is composed of 126 bones. Pectoral (shoulder) girdle is made of 4 bones. Arms have 6 bones. Both hands have 54 bones. Pelvic girdle (hips) has 2 bones. Legs have 6 bones. Both feet have 54 bones.

Practical:

Identify and draw labelled diagrams of different bones of the human skeleton from real specimens, models or charts.

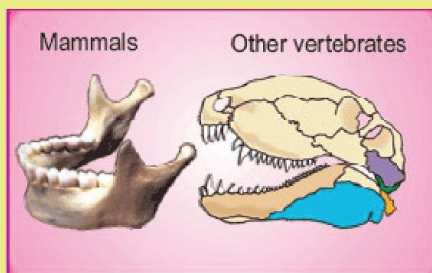


Painting from Vesalius book

Andreas Vesalius (1514-1564) is honoured for developing modern anatomical studies. Vesalius was born in Brussels, Belgium. He made many discoveries in anatomy, based on studies made by dissection of human dead bodies. His book contained the most accurate depictions of the whole skeleton and muscles of the human body.

Do you know?

The upper jaw is fixed with the skull and is composed of two bones. The lower jaw is mobile and articulates with the skull. In lower vertebrates, the lower jaw is made up of more than one bone while in mammals, it is made of single bone. During evolution, mammals modified the lower jaw bones and incorporated four of them into the middle ear (in the form of malleus and incus in both ears). This adaptation proved beneficial for mammals. Lower jaw with single bone is stronger and the malleus and incus also improve hearing.



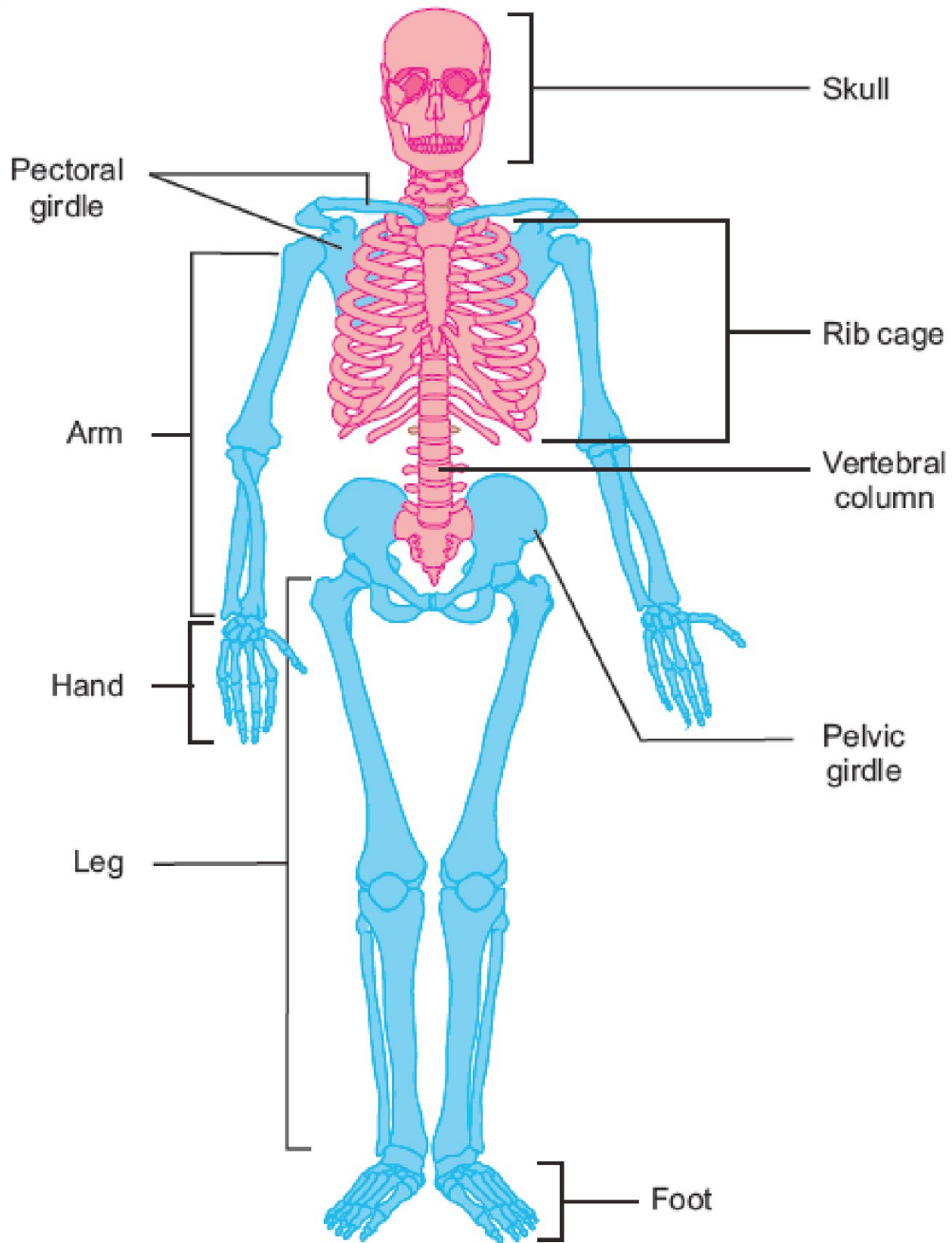


Figure 13.6: Human skeleton

You can see in the diagram. The thigh bone is the longest bone in our body. Recall your knowledge and name the smallest bone.

13.2 Types Of Joints

A joint is the location at which two or more bones make contact. They allow movement and provide mechanical support. Joints can be classified on the basis of the degree of movement they allow.

Immoveable (Fixed) joints: Such joints allow no movement e.g. the joints between the skull bones.

Slightly moveable joints: Such joints allow slight movements e.g. joints between the vertebrae.

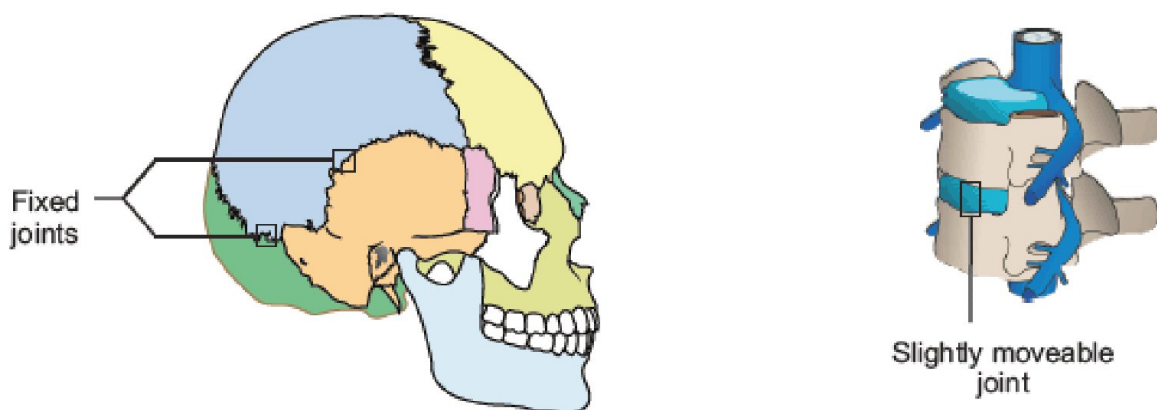


Figure 13.7: Fixed and slightly moveable joints

Moveable joints: They allow a variety of movements e.g. shoulder joint, hip joint, elbow joint, knee joint etc. There are many types of moveable joints in body. The main types are hinge joints and ball-and-socket joints. **Hinge joints** move back and forth like the hinge on a door and allow movements in one plane only. The knee and elbow are hinge joints.

Ball-and-socket joints allow movement in all directions. The hip and shoulder joints are ball-and-socket joints (Fig. 13.8).

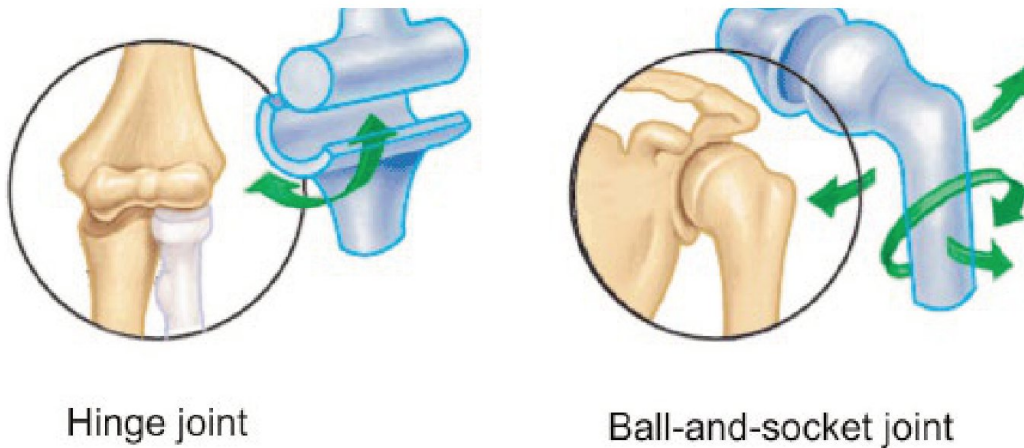


Figure 13.8: Two types of moveable joints

Practical:

Observe models for the movements at joints and describe how joints allow various movements.

The neck joint between vertebral column and head allows movements side to side. Can you think what would have happened if it were a ball-and-socket joint?

13.2.1 Roles of Tendons and Ligaments

Tendons and ligaments are bands of connective tissue (made of collagen). Tendons are tough bands and attach muscles to bones. When a muscle contracts tendon exerts a pulling force on the attached bone, which moves as a result. Ligaments are strong but flexible bands and join one bone to another at joints. They prevent dislocation of bones at joints.

Animation 13.8: Knee
Source & Credit: Wikipedia

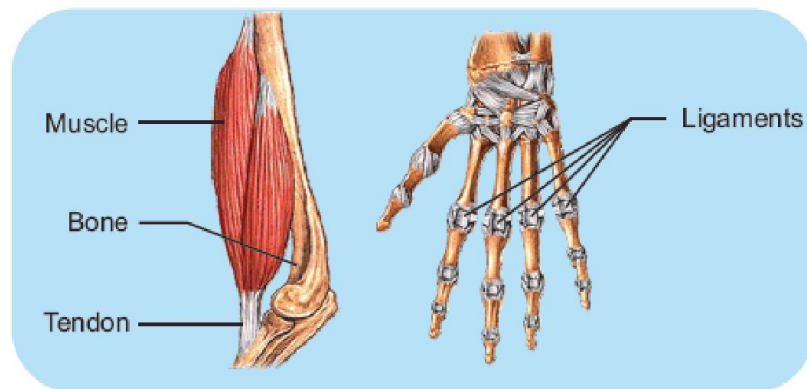


Figure 13.9: Tendons and ligaments

It is important to remember that muscles can only pull or contract, not push.

Most activities in our body like standing, walking, running, playing etc. require combined action of several muscles.

13.3 Muscles And Movement

We know that when bones move at joints, they produce movements. The movements in bones are brought about by the contractions of skeletal muscles, which are attached with them by tendons. The role of skeletal muscles is as follows.

One end of a skeletal muscle is always attached with some immovable bone. This end of muscle is called the origin. Other end of muscle is attached with a moveable bone and is called the insertion. When a muscle is stimulated by a nerve impulse, it contracts to become shorter and thicker. Due to this contraction, it pulls the moveable bone (at insertion).

Skeletal muscles are usually in pairs of **antagonists**. In an antagonistic pair, both muscles do opposite jobs. When one muscle contracts the other relaxes and this phenomenon is known as antagonism (antagonistic action). When a muscle contracts and bends the joint, it is known as flexor muscle and the movement is called **flexion**. When a muscle contracts and straightens the joint, it is known as extensor muscle and the movement is called **extension**. Following is an example of the antagonistic action of a pair of skeletal muscles.

Biceps is a flexor muscle on the front of the upper arm bone while Triceps is an extensor muscle on the back of arm.

Both these muscle have their origin at pectoral girdle and insertion at one of the two bones of forearm. When biceps contracts, the forearm (insertion end) is pulled upward. It is the flexion of elbow joint. During this flexion, triceps muscle relaxes. When triceps muscle contracts, forearm is pulled down. It is the extension at elbow joint. During it, biceps muscle relaxes (Fig. 13.10). In this way, biceps and triceps make up an antagonistic pair of muscles. Similar pairs, working antagonistically across other joints, provide for almost all the movements of skeleton.

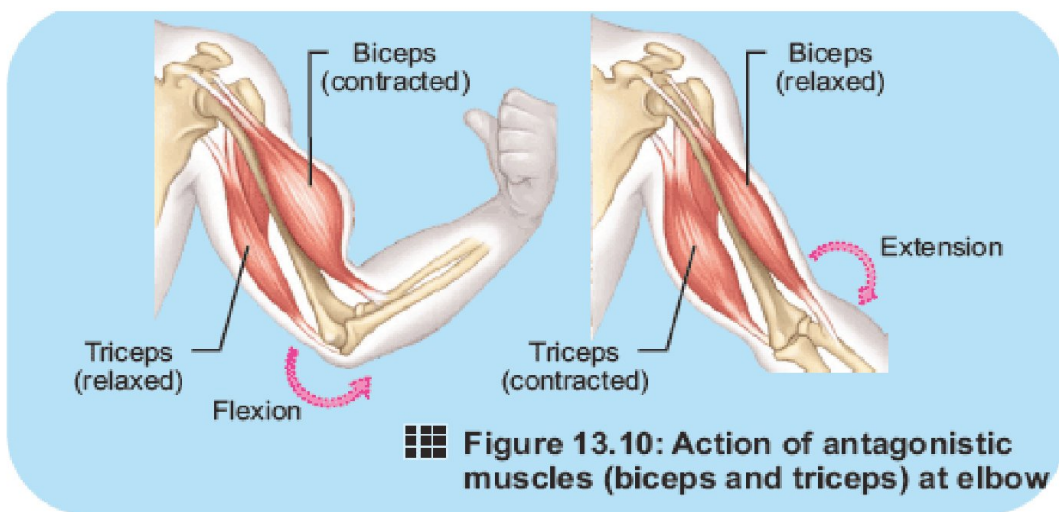


Figure 13.10: Action of antagonistic muscles (biceps and triceps) at elbow

? Which point of attachment is pulled when a muscle contracts?
 What point of attachment is pulled when a muscle contracts?
 Insertion

Practical:

Describe the movement of biceps and triceps through presentation of the movement of your elbow joint.

Can you do it?

Aquatic animals need less skeletal support than land animals of similar size. Propose an explanation for this fact.

13.4 Disorders Of Skeletal System

The following disorders of skeletal system are important.

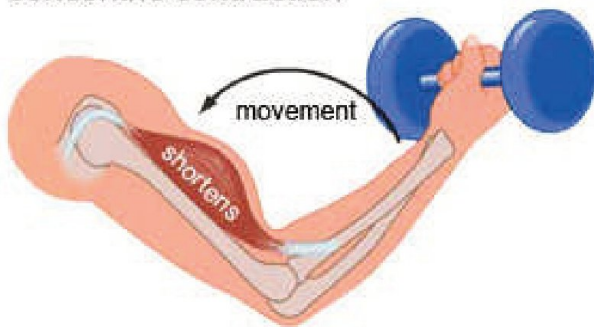
13.4.1 Osteoporosis

Osteoporosis is a bone disease in adults, especially in old people. It is more common in old women. In osteoporosis, there is a decrease in the density of bones due to loss of calcium and phosphorus. It may be due to malnutrition (lack of proteins and Vitamin C), lack of physical activities or deficiency of estrogen hormone.

It is one of the functions of estrogen to deposit minerals in bones. When the reproductive cycle stops in females, not enough estrogen is secreted.

In old age, there is decreased secretion of growth hormones and it also leads to decreased deposition of minerals in bone matrix.

concentric contraction



Animation 13.13: Contraction, Source & Credit: Letsmakerobots

Animation 13.12: Muscles and Movement
Source & Credit: Jeron

13.4.2 Arthritis

Arthritis means “inflammation in joints”. It is also very common in old age and in women. It is characterised by pain and stiffness in joints (particularly in the weight bearing joints e.g. hip joint, ankle joint etc.). The treatment of arthritis includes pain killer and anti inflammatory medicines. There are many types of arthritis, for example:

1. Osteo-arthritis: It is due to degeneration in the cartilage present at joints or due to decreased lubricant production at joints. In this arthritis, fusion of the bones at joint may occur and joints may become totally immovable.

2. Rheumatoid arthritis: It involves the inflammation of the membranes at joints. Its symptoms include fatigue, low-grade fever, pain and stiffness in joints.

3. Gout: It is characterised by the accumulation of uric acid crystals in moveable joints. It generally attacks the toe joints.

Practical:

Investigate the chemical nature of bone

The bone matrix carries most of its mass. It contains large amounts of calcium.

Hypothesis: The bone matrix contains calcium.

Deduction: If a bone is placed in acidic solution, its calcium will get dissolved and bone will become porous.

Apparatus: Three rib bones of goat, Petri dish, beaker, 20% HCl, 20% NaOH, distilled water

Procedure:

- Take three Petri dishes and mark them 'A', 'B' and 'C'.
- Place one rib bone in each of the dishes.
- Add distilled water in dish 'A', HCl in dish 'B' and NaOH in dish 'C'.
- Keep the apparatus as such for 2 hours.

Observation:

Observe the bones in the three Petri dishes.

- The bones in Petri dishes 'A' and 'C' do not show any change while the bone in dish 'B' becomes much weaker and porous.

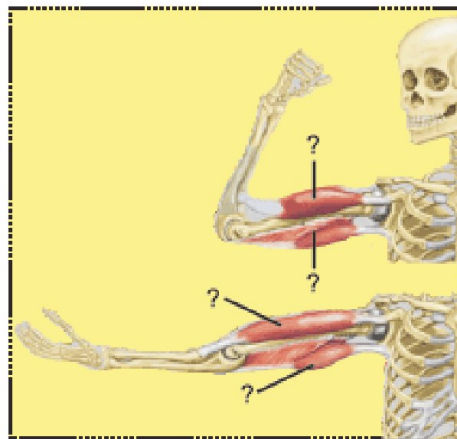
Results: The observation indicates that bone is made of calcium (in the form of CaCO_3). HCl reacts with CaCO_3 and dissolves it.

UNDERSTANDING THE CONCEPT

- What are the main components of the axial skeleton and the appendicular skeleton of human?
- Describe the types of joints and give examples.
 - What are ligaments and tendons? What function do they perform?
 - Explain antagonism in muscle action selecting biceps and triceps as example

SHORT QUESTIONS

- Differentiate between cartilage and bone.
- What is the role of skeleton in support and movement?
- How would you differentiate between osteoporosis and arthritis?
- Label the biceps and triceps in the following diagrams and also mention their contracted or relaxed states.



THE TERMS TO KNOW

<u>Antagonism</u> <u>Appendicular skeleton</u> <u>Arthritis</u> <u>Axial skeleton</u> <u>Ball-and-socket joint</u> <u>Biceps</u> <u>Bone</u> <u>Cartilage</u> <u>Chondrocyte</u> <u>Compact bone</u> <u>Cranial bones</u> <u>Extensor</u> <u>Fibrous cartilage</u>	<u>Flexor</u> <u>Gout</u> <u>Hinge joint</u> <u>Hyaline cartilage</u> <u>Insertion</u> <u>joint</u> <u>Lacuna</u> <u>Ligament</u> <u>Origin</u> <u>Osteoarthritis</u> <u>Osteocyte</u> <u>Osteoporosis</u>	<u>Rheumatoid arthritis</u> <u>skeleton</u> <u>spongy bone</u> <u>Sternum</u> <u>Tendon</u> <u>Triceps</u>
--	---	---

ACTIVITIES

1. Identify and draw labelled diagrams of different bones of the axial and appendicular skeleton from real specimen models or charts.
2. Describe the movement of various human joints through observation of models.
3. Describe the movement of biceps and triceps through presentation of the movement of your elbow.
4. Investigate the chemical nature of bone (by putting three pieces of rib bone of lamb or goat in water, NaOH and dilute HCl).

SCIENCE, TECHNOLOGY AND SOCIETY

1. Relate your skeleton with its functioning in daily life.
2. Relate the principle of leverage to the action of elbow joint.
3. State the principles of arthroplasty for the replacement of joints.